

ACCENT[®]XLI



The Accent XLi is intended for:

- Improvement in the appearance of cellulite
- Circumference reduction
- Fat reduction
- Post liposuction treatments
- Stretch Marks
- Pain Therapy and Sports Medicine

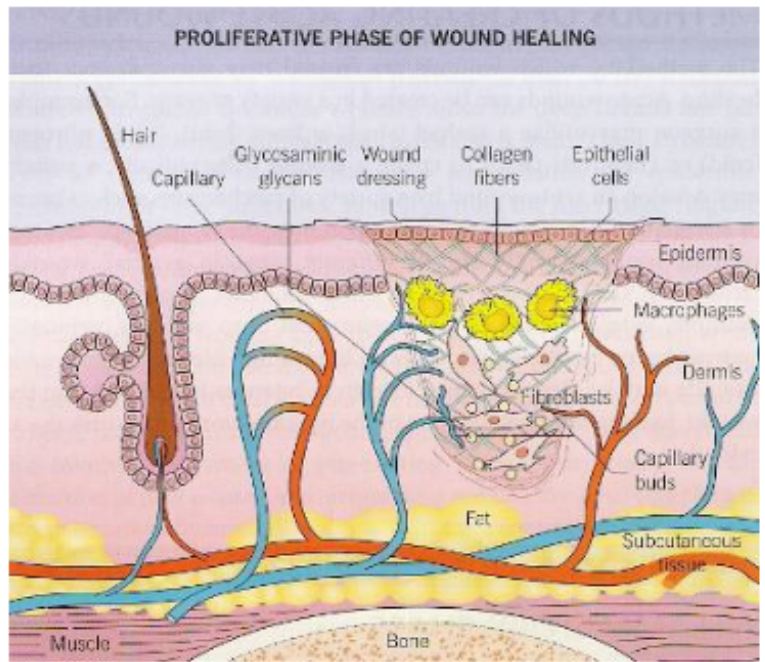
- Skin Tightening
- Improvement in the appearance of wrinkle
- Improvement in skin texture
- Pore reduction
- Acne treatment
- Treatment of scars, including acne scars

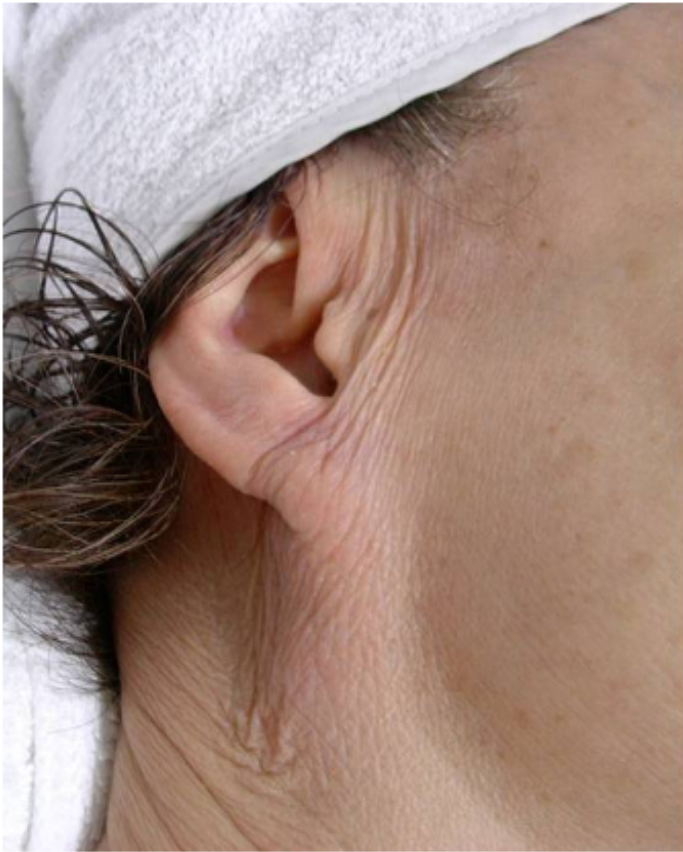Skin Tightening

Heating
↓
Collagen Contraction
↓
Neocollagenesis

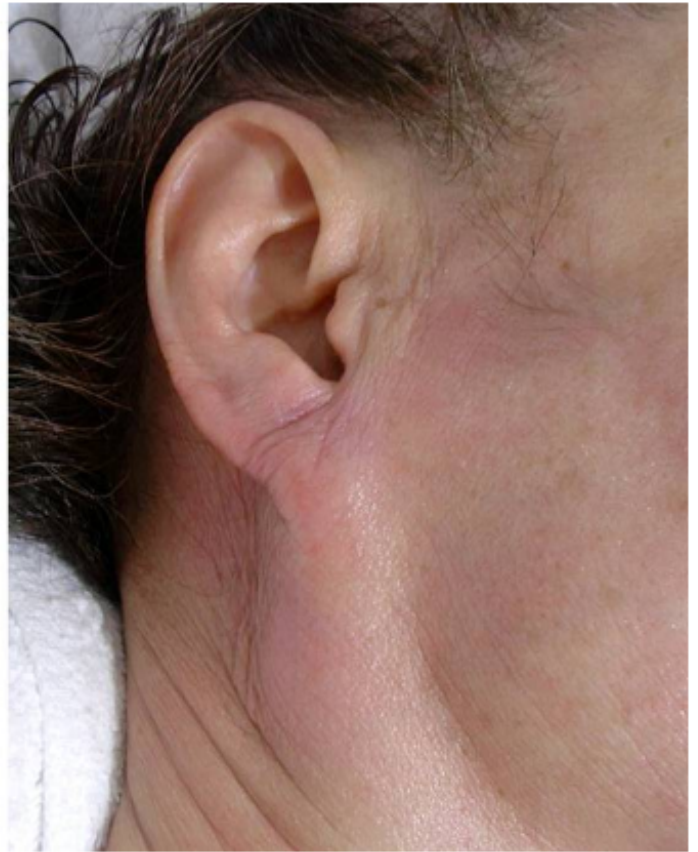Bipolar →

Unipolar →





Before



2 weeks after 5 Txs, 2 weeks apart

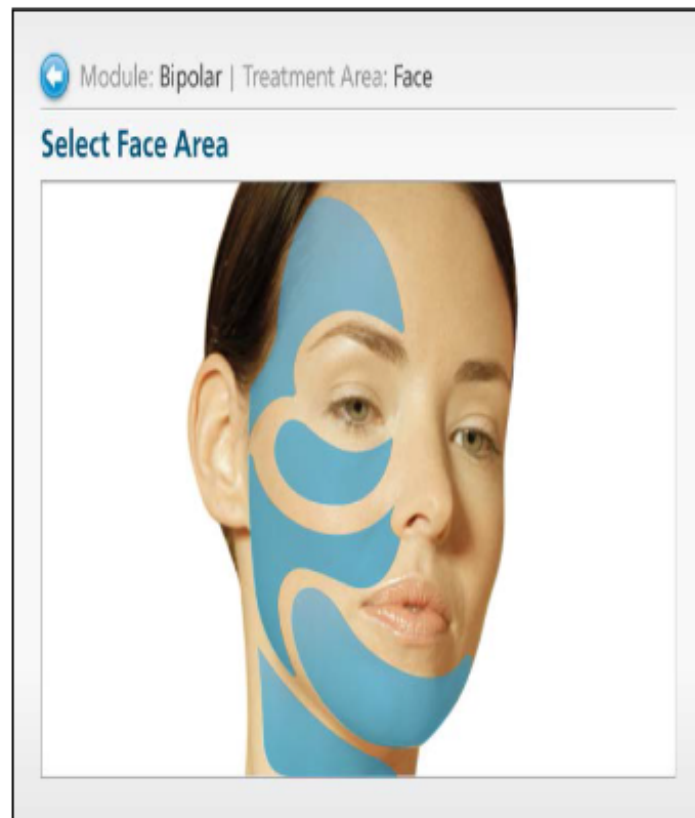
Face Protocol

Main Indications:

1. Skin Tightening
2. Improvement in the appearance of wrinkle
3. Improvement in skin texture

Treatment Technique:

- Using small circles.
- When combined start with Unipolar and finish with Bipolar.
- Typical treatment at 70-100W for Unipolar, 50-70W for bipolar.



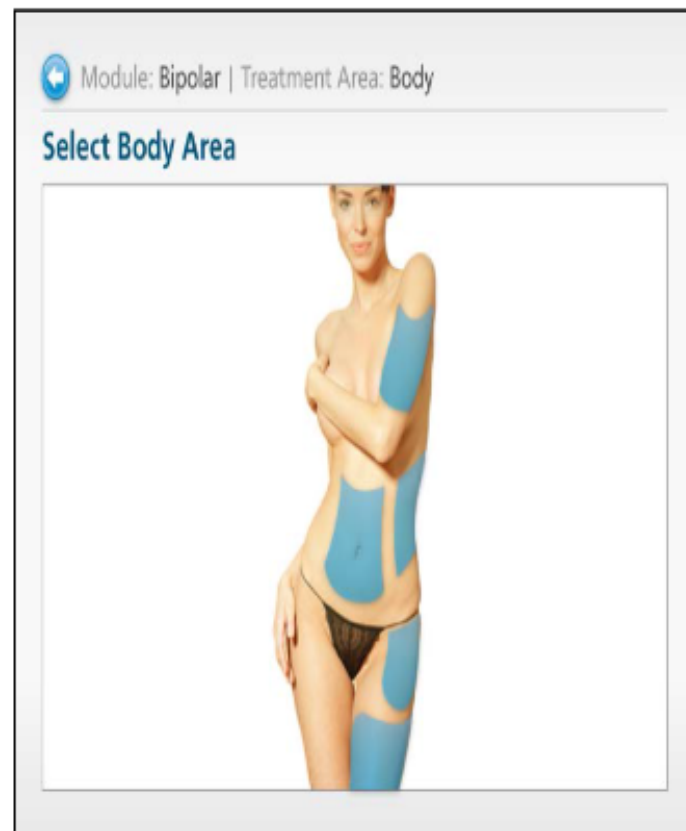
Body Protocol

Main Indications:

1. Fat reduction
2. Circumference reduction
3. Cellulite improvement
4. Body contouring
5. Improvement in skin texture

Treatment Technique:


- Using big circles.
- When combined start with Unipolar and finish with Bipolar.
- Typical treatment at 130-180 W for Unipolar, 70-90W for bipolar.



AccentXLi Treatment Areas

- Face
- Neck (avoid thyroid gland area!)
- Body
 - Abdomen
 - Waists
 - Arms
 - Thighs
 - Buttocks
 - Back

Fat Reduction



Modes:
Deep + Superficial

Cellulite



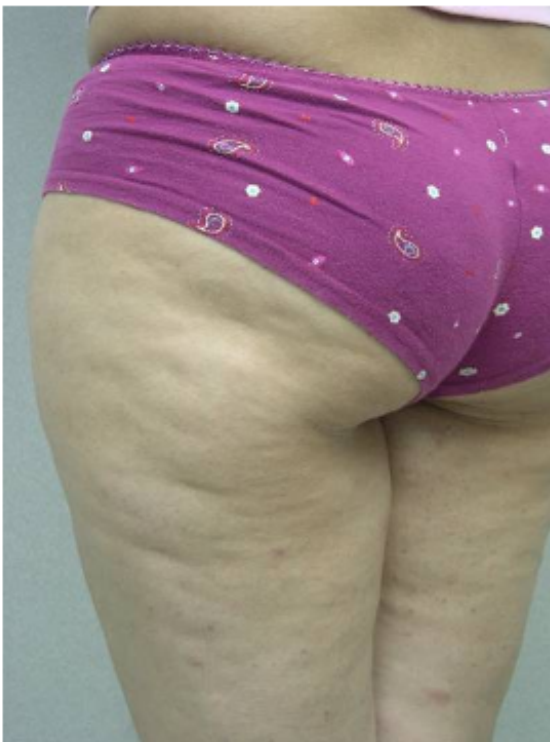Modes:
Medium + Superficial

Skin Laxity

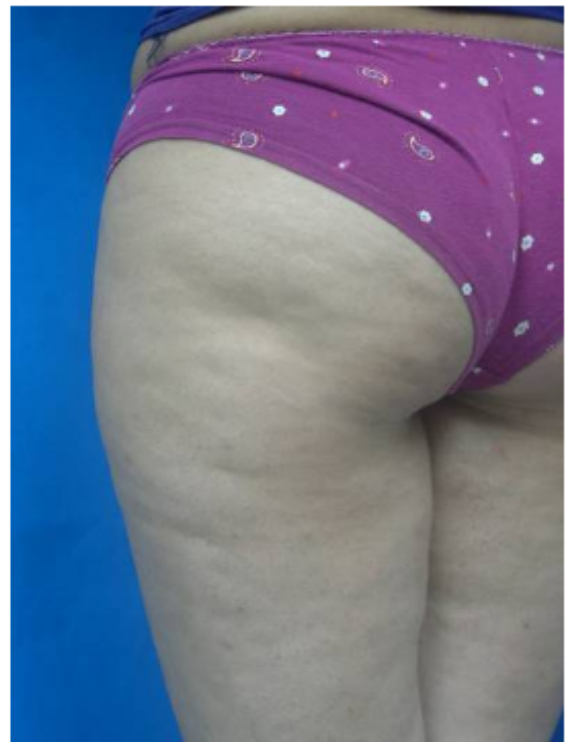

Mode:
Superficial

Before



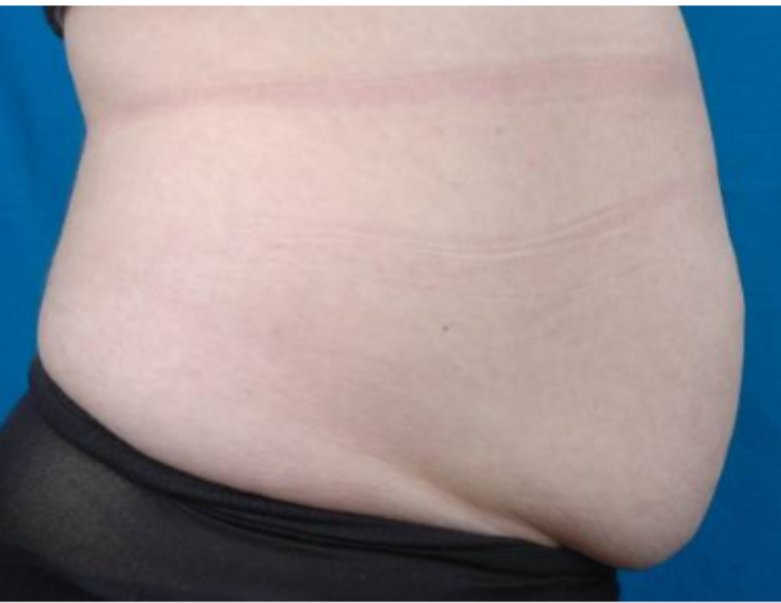After 3 Tx



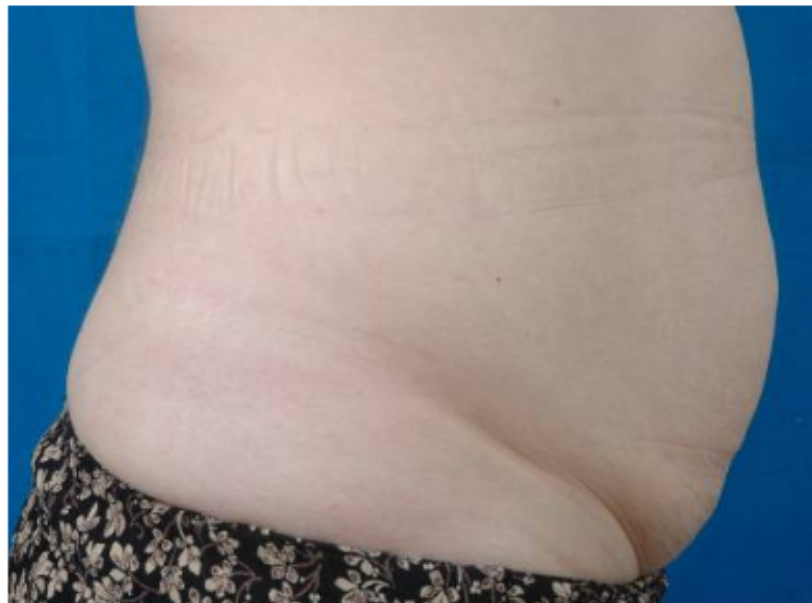Photos courtesy: Dr. J. Lepselter, Dr. Yaron Assaf,
Beit Harofyim, Hadera, Israel

Cellulite Treatment Protocol

- 39°C minimal therapeutic temperature
- Maintaining 40°C-44°C until the recommended amount of total energy is invested in the treated grid

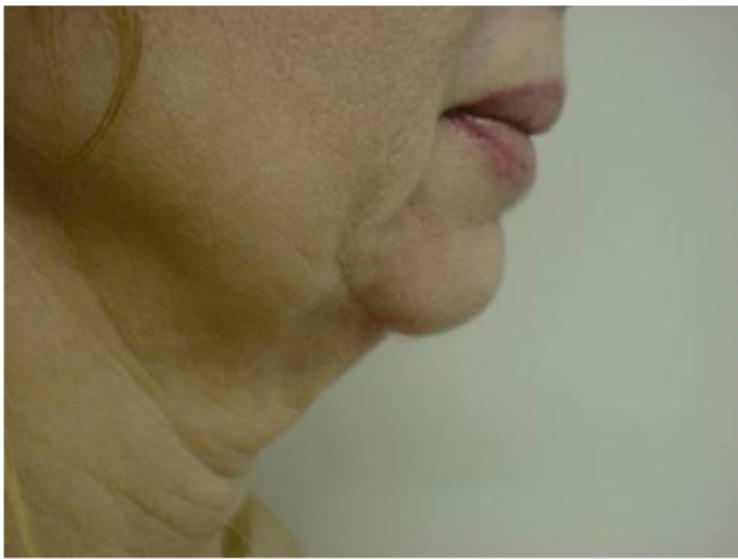

Before

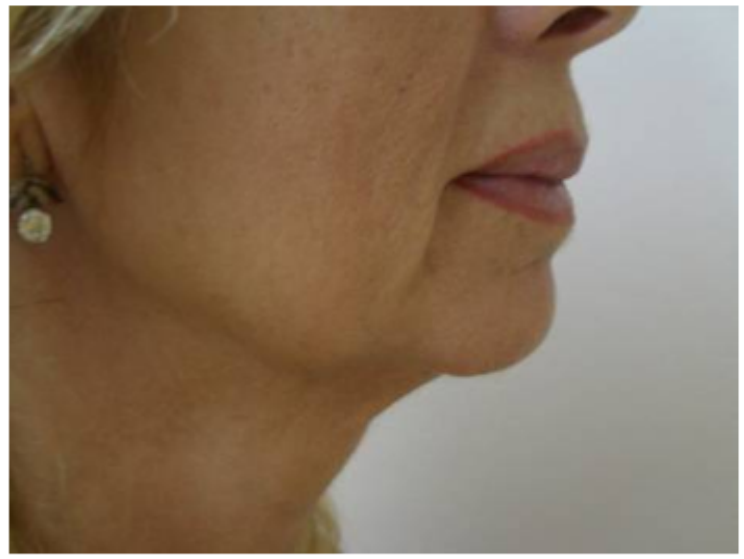

2 Mo. after 3 Tx, 3 weeks apart;
Unipolar

Photos courtesy: Dr David Friedman, Jerusalem, Israel



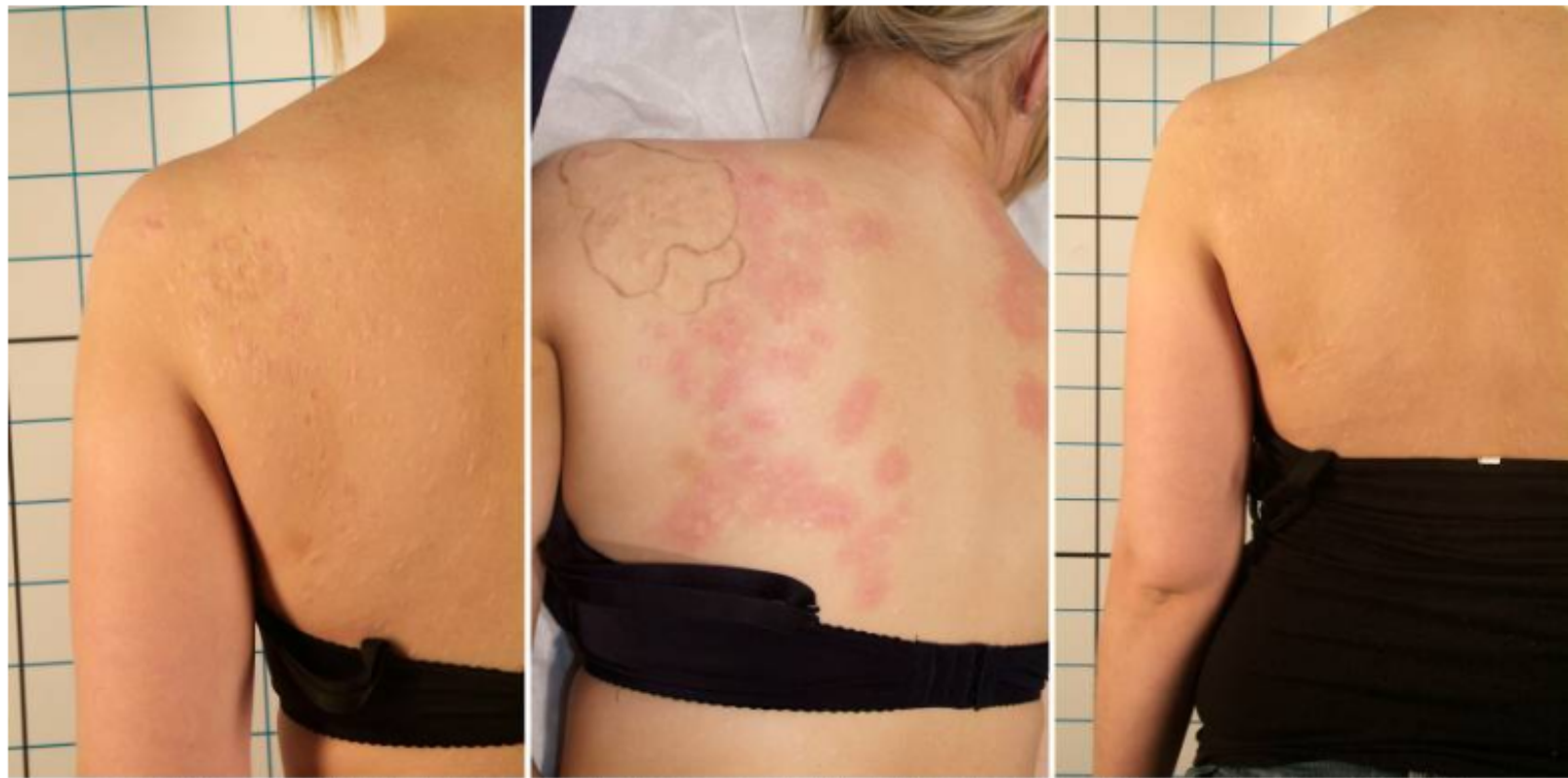Before



3 weeks after 1 Tx; Unipolar

Photos courtesy: Dr. Diego del Ojo, Spain

Acne Scars



Accent Radio Frequency based Pixel treatment, patient 22 year old female with long term acne scarring. Left image prior to treatment, centre during treatment 2 and 3, right after 4 weeks after treatment 3.

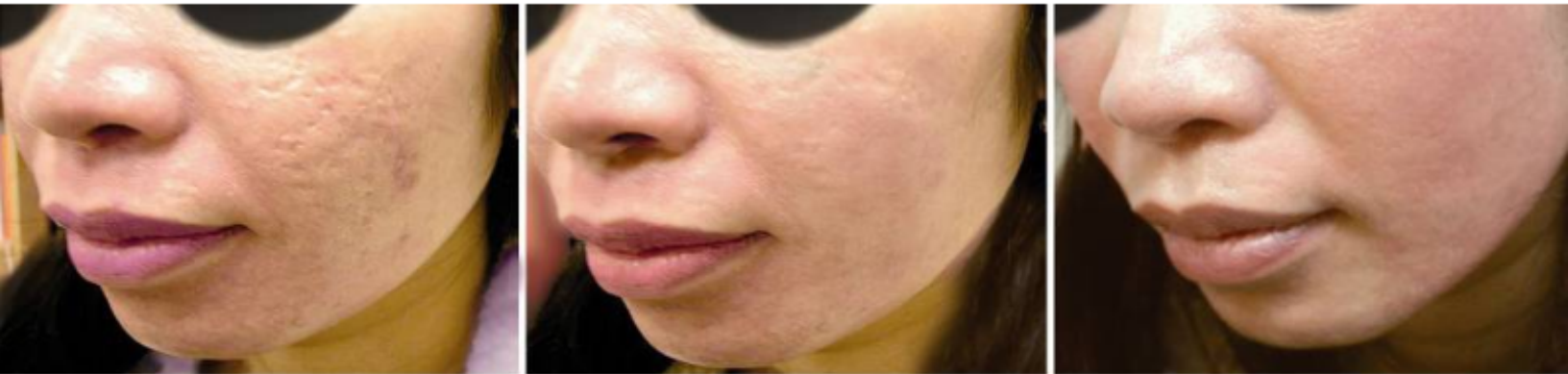Image courtesy of Gary Plumley Aesthetica Image Centre, Melbourne Australia.

Acne Scars

Before

After 5 treatments

After 6 treatments

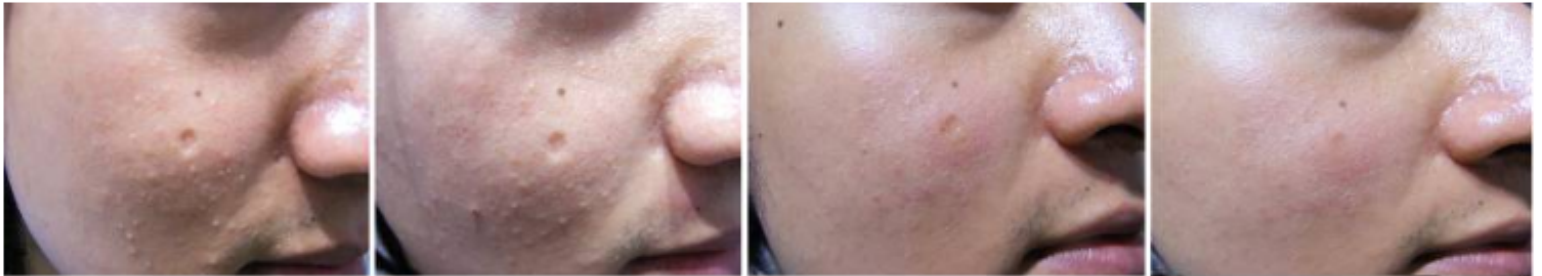

Accent Pixel RF treatment case history. Patient 33 year old Asian female with long term acne scarring to face. Image 1 as patient presented for treatment. Image 2 after 5 treatments approximately 2 weeks apart.

The final image is the patient after the sixth treatment and a course of microdermabrasion and LED red light therapy. The patient will be maintained with appropriate take home skin care treatments.

Images courtesy of Aesthetica Image Centre, Melbourne Australia

Chicken Pox Scars



Accent Pixel RF treatment case history. Patient 19 year old male with deep recessed chicken pox scar to right cheek. Patient also displayed low level active acne. Treatment was 5 sessions of Pixel PF with smallest stationary tip, with 2 stacked 1 second exposures, then 5 single feathered exposures to the edges, all at 60 watts. 2 Unipolar RF passes also, to clear up acne. Patient treated with LED light for 20 minutes after each session. Images courtesy Aesthetica Image Centre. Melbourne. Australia